

Ultrasound-Guided Intermediate Cervical Plexus Block effects on per and Post-Operative Opioids Consumption during Total Thyroidectomy under General Anesthesia

Ali Majdoub^{1*}
Mouna Ouaz¹
Hela Attia¹
Nouha Ben Hmida²
Nabil Driss²

¹ Intensive care department in mahdia hospital Tunisia, Tunisia.

² ENT department in Mahdia hospital Tunisia, Tunisia.

Abstract

Background: Ultrasound-guided intermediate cervical plexus block (ICB) recently described seems to be promising, we aim to clarify the contribution of this block on reduction of opioids consumption in per and post-operative periods during thyroidectomy under general anesthesia and to determine the impact on analgesia, the resulting adverse effects and patient satisfaction.

Methods: Seventy patients were included in a prospective observer-blinded trial and randomized to be allocated to:

- Group 1 (GP1): bilateral echo-guided ICB by 10 ml of isobaric Bupivacaine (0.25%). (35 patient) realized 10 minutes before general anesthesia.

- Group 2 (GP2): control (35 patients).

- Total dose of Remifentanyl is calculated upon awakening, the postoperative pain is determined by visual analogic scale from 0 to 10 (VAS) statements to H0, H2, H4, H6, H12 and H24. Whenever EVA is greater than or equal to 4, a morphine titration was administered; total dose consumption, side effects and satisfaction are noted at the end of the protocol.

Results: Pre-operative opioid consumption was significantly decreased by more than 38% for GP1. The post-operative morphine titration request in GP1 was noted for 10 patients VS 21 in GP2. We noted nausea and vomiting for 9 patients in GP1 against 13 in GP 2.

The VAS at H1 and after H12, was significant statistically higher for GP2. For GP1, 75% were satisfied VS 58% for GP2.

Conclusion: ICB for total thyroidectomy under general anesthesia allows per and post-operative opioids

decreasing, provides a better analgesia and reduces adverse events. This technique seems to better patient 'satisfaction.

Keywords: Cervical plexus, Anesthesia, Thyroidectomy, Opioids.

Introduction

The cervical block is one of the loco-regional anesthesia techniques described for thyroid and other cervical surgery, both for anesthetic and analgesic goals [1-4]. The intermediate cervical block keeps its indications in this painful known surgery with postoperative pain scales ranging from 6 to 7/10 on a visual analogic scale [2]. The literature review found several proposed analgesic protocols with contradictory

Article Information

Article Type: Research

Article Number: JBRR104

Received Date: 06 March, 2018

Accepted Date: 22 April, 2018

Published Date: 29 April, 2018

***Corresponding author:** Dr. Ali Majdoub, Intensive Care Unit, University Hospital Taher Sfar Mahdia 5100; University of Monastir, Research Laboratory, LR 12SP15, Tunisia, Tel: +91 21650030022; Email: [majdlee2013\(at\)gmail.com](mailto:majdlee2013(at)gmail.com)

Citation: Majdoub A, Ouaz M, Attia H, Hmida NB, Driss N (2018) Ultrasound-Guided Intermediate Cervical Plexus Block effects on per and Post-Operative Opioids Consumption during Total Thyroidectomy under General Anesthesia. J Biomed Res Rev Vol: 1, Issu: 1 (31-35).

Copyright: © 2018 Majdoub A. This is an open-access article distributed under the terms of the Creative Commons Attribution License, which permits unrestricted use, distribution, and reproduction in any medium, provided the original author and source are credited.

results [2-5]. The anticipation of analgesia begins in per-operative, not only by the administration of analgesics but also by the reduction in the need for opioids thus reducing the phenomena of tolerance and hyperalgesia. Our main objective was to determine the effect of the intermediate cervical plexus ultrasound-guided block, on the per- and post-operative consumption of opioids during thyroidectomy under general anesthesia. The secondary aim was to evaluate its impact on adverse effects and on patient satisfaction.

Patient and Methods

We conducted a prospective, randomized observer-blinded study. After approval of the local ethics committee, and informed consent of the patients, we included: patients with physical status ASA I or II, over 18 years old and proposed for simple total thyroidectomy. The criteria for non-inclusion were ASA > II, renal insufficiency with creatinine clearance <30 (calculated by the Cockcroft formula [6], pregnant women, allergy to bupivacaine, obesity with BMI > 40, Patient already under long-term morphinomimetics. Patients were randomized to be allocated to one of the two groups (35 patients in each group): Group 1 (GP1) bilateral echoguided block of the intermediate cervical plexus with 10 ml of 0.25% isobaric bupivacaine in each side. Group 2 (GP2) control group. Before the beginning of surgery, a random draw is made by a nurse from the department for randomization using the opaque envelope method. All patients were pre-medicated with hydroxyzine 1 mg. Kg-1 per os 02 h before the intervention. At the recovery room, after having placed a peripheral venous route, an infusion of isotonic saline serum was started. Standard monitoring by electrocardiogram, pulse oximeter and automatic non-invasive blood pressure measurement were installed.

The patient was placed in supine position, with the head slightly turned to the opposite side to the puncture after disinfection with Chlorhexidine. A linear ultrasound probe (Esaote: L12-5L40H Frequency 12 MHz) protected by a Sleeve initially was placed at the level of the hyoid bone to visualize the vascular axis of the neck. Secondly, it was translated in the cephalic direction until the visualization of the carotid bifurcation. Subsequently, a lateral scan was made with respect to the vascular axis to visualize the body of the sternocleidomastoid muscle (SCM) which was separated from the deep muscles of the neck by a hyperechoic space corresponding to the posterior cervical space where the Various branches of the superficial cervical plexus. This space corresponds to our target (Figure 1). Puncture was made in the plane by a posterior approach to the lateral edge of the SCM muscle using a needle (50 mm vygon) the ten ml of the local anesthetic were injected from the depth to the surface (Figure 2). This same gesture was repeated on the contralateral side.

After 10 minutes, anesthetic induction was carried out with 3 mg / kg of Propofol, 1 µg / kg of remifentanyl. Orotracheal intubation was facilitated by 0.15 mg / kg of cisatracurium.

In addition to the monitoring already installed, we

associated that of narcosis (BIS, Covidien LLC. Mansfield, USA) whose level was maintained between 40 and 60, a monitoring of the end tidal CO₂, maintained between 35 and 40mmHg, we associated a gas analyzer.

The maintenance of the anesthesia was done by sevoflurane adjusted according to the values of the bispectral index. The patient was ventilated with a 50/50 O₂ / N₂O mixture. Remifentanyl was administered by the automatic pump as a function of the variation in blood pressure and heart rate, which should not exceed 20% of their baseline values during the surgical procedure.

All our patients were operated by the same team.

Ten minutes before closure, each patient received 1 g of paracetamol and 50 to 100 mg of tramadol depending on his weight. The remifentanyl automatic pump was stopped when the skin was closed, and the total dose was calculated for each patient.

Upon awakening, the hemodynamic parameters were

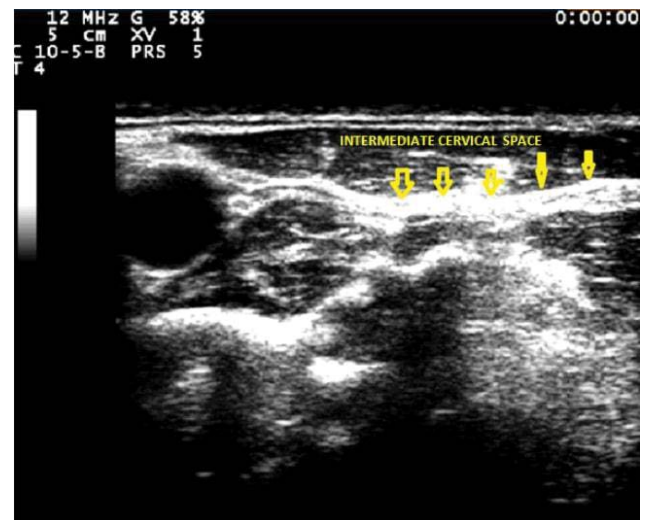


Figure 1: Space corresponding to target.

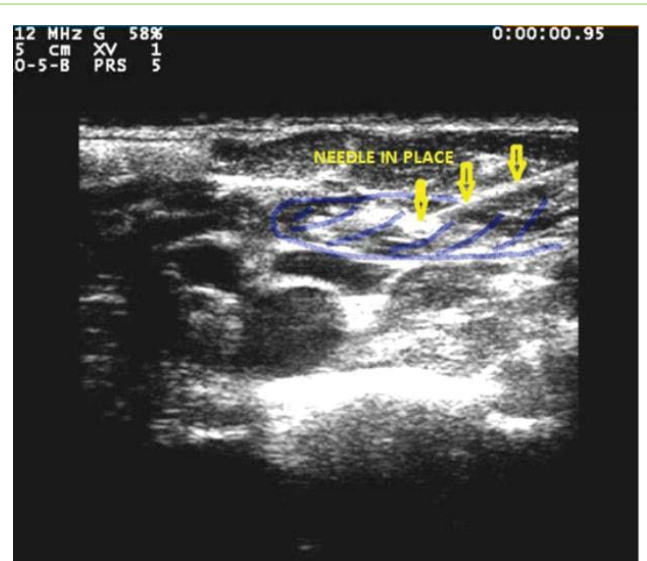

Figure 2: Needle in the space and injection procedure.

noted, as well as the assessment of pain at rest by the visual analog scale which ranged from 0 (absence of pain) to 10 (intolerable pain). The evaluation of pain was done at H0, H2, H4, H6, H12 and H24 by a referral anesthesia technician in pain management.

Each time the patient had an VAS greater than or equal to 4, a titration of morphine [7] was carried out by 3 mg IV every 5 minutes until an VAS <4 was obtained. The titration was stopped because of intolerable nausea or vomiting or if the patient became drowsy or had a respiratory rate <10 / min. The total dose of morphine required for titration was calculated. We also noted adverse events such as nausea, vomiting and bleeding. The patients were then transferred to the department. Analgesia was provided by paracetamol 1g every 06 H and tramadol 50 to 100 mg every 12 h intravenously.

Our primary endpoint was pre and post-operative opioids consumption, secondary endpoints were VAS at first awakening, adverse events (nausea / vomiting), and patient satisfaction at discharge.

The input and statistical analysis was done using SPSS 20.0 software. The continuous variables were compared by the student T test, the qualitative variables by the test of Qi two. The VAS was expressed as a median and interquartile range (25-75).

P <0.05 was considered significant.

Results

Over a period of 20 months from the beginning of March 2014 to the end of November 2015 we have included 70 patients. The analysis was made only for 29 patients in the cervical block group GP1 because of difficulty in realizing the block for 04 patients (space not visualized) and difficult follow-up for two others, due to pre-operative difficulties and absence of Post-operative cooperation.

For the control group GP2, the analysis was performed for only 31 patients. For three patients, the follow-up was impossible due to lack of post-operative cooperation and wakening difficulties. For one patient, the monitoring was interrupted at H2 due to reoperation for a hematoma of the lodge (see flow-chart) Figure 3.

Demographic, anthropometric, ASA and surgical duration were comparable in both groups (Table 1).

Intra-operative intake of remifentanyl was significantly reduced by more than 38% in GP1. The titration of morphine was done only during the period of stay in the recovery room.

The demand for post-operative morphine titration in the GP1 group was noted in 10 patients whereas in the control group it was noted in 21 patients with an average dose decreased by more than 30% in the GP1 group (Table 2). We also noted nausea and vomiting in nine patients in the GP1 group versus thirteen in the GP 2 group with an incidence that did not differ statistically significantly from 31% to 41%. P = 0.38. (Table 2).

VAS on awakening and from H12 was statistically higher

in the control group with a significant difference. However, at postoperative H1, H2 and H6, the difference was not significant (Table 3).

As for overall satisfaction, in the GP1 group, 22/29 patients (75%) were satisfied, whereas in the control group, only 18/31 patients (58%) were satisfied. The difference was not statistically significant p = 0.17.

Discussion

In our prospective randomized study, we observed that the realization of intermediate cervical plexus ultrasound-guided block, for thyroidectomy under general anesthesia allowed a reduction in the per-operative consumption of remifentanyl by more than 38%, a lesser use of the Morphine postoperative titration with a total dose reduction of more than 30%, and me allow to a better immediate postoperative analgesia and increase of patient satisfaction. Thyroid surgery may cause discomfort and severe postoperative pain for the patients [8], particularly in immediate postoperative period with an intensity ranging from 55 to 78 on the visual analogic scale (VAS) ranging from 0 to 100. The peri-operative opioid regimen had an influence on the intensity of post-operative pain [9]. In our series, the post-operative VAS was on average 50 on a scale ranging from 0 to 100 in the control group. The contribution of the cervical plexus block during this surgery remains controversial and recommendations for its use remain blurred. Such a divergence is related to the variability of techniques and procedures [2]. This difference would be related to interfacial blind infiltration performed by non-echo-guided techniques [10-12] with success average in order of 14% [13].

We report a simple technique of realization, but dependent on the anatomical variants. In our series, the success rate

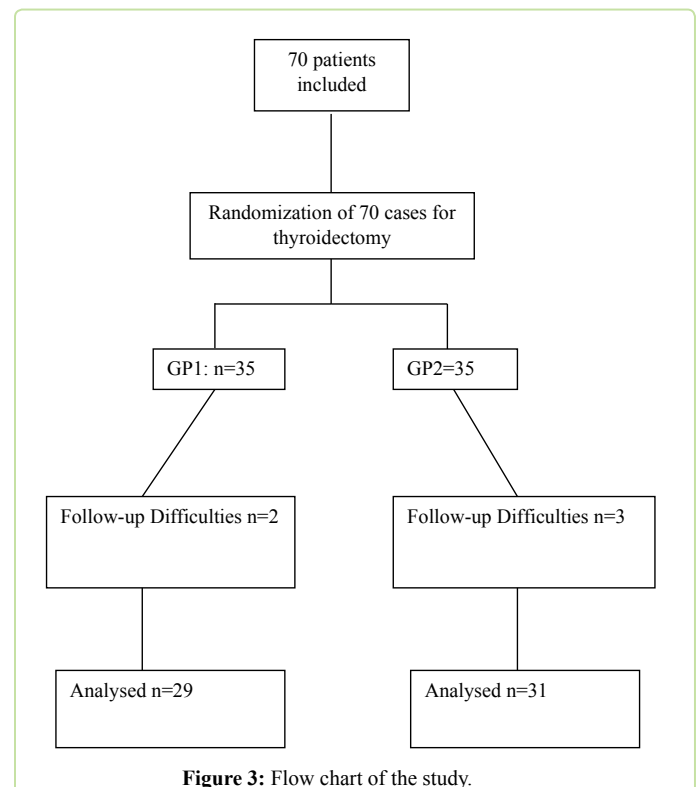


Figure 3: Flow chart of the study.

Table 1: Demographic data.

	GP 1 (n=29)	GP 2 (n=31)	P
Age (years \pm SD)	44,9 \pm 18,5	46,2 \pm 22,9	NS
Sex (M/F)	11/18	10/21	NS
Weight (kg \pm SD)	76,13 \pm 17,9	80,5 \pm 12,5	NS
ASA I/II	16/13	23/8	NS
Duration of surgery (min \pm SD)	89,3 \pm 19,8	83,7 \pm 25,8	NS

Table 2: Opioids consumption of undesirable effect and patient's satisfaction.

	GP1 (n=29)	GP2 (n=31)	P
Per op Remifentanil (ug \pm SD)	828 \pm 192	1350 \pm 494	<0.001*
Post op Morphine (mg \pm SD)	2,27 \pm 3,06	4,1 \pm 3,47	0.037*
Morphine YES/NO	10/19	21/10	0.010*
PONV YES/NO	9/20	13/18	0.38
Satisfaction YES/NO	22/7	18/13	0.17

*Significant difference

Table 3: Post operative evolution of VAS.

VAS	GP1 (n=29)	GP2 (n=31)	P
H0	4 (3-5)	5 (4-7)	0.005*
H1	4 (3-5)	4 (3-5)	0.13
H2	4 (3-4)	4 (3-5)	0.221
H6	3 (3-4)	4 (3-4)	0.415
H12	3 (2-3)	3 (3-4)	0.009*
H24	3 (2-3)	3 (3-4)	0.008*

*Significant difference

was 90%. In a series of anatomical study of cadavers, the authors report five successes (confirmed by the injection of blue methylene) on the 6-intermediate cervical ultrasound-guided blocks. Secondary dissection shows a correct diffusion affecting all the sensitive branches from C2 to C4 [14]. In a recent series, for carotid surgery, a success rate of 90% is reported [15]. Intermediate cervical plexus block appears to be a promising technique in terms of anesthesia and analgesia during thyroidectomy [1,16]. The various studies focused on the contribution of the cervical block to post-operative analgesia, using as a measuring tool the amount of morphine consumed in the postoperative period [2-17]. However, none of them reported its contribution to the saving of opioids per-operative consumption, especially since postoperative pain is directly related to the regimens and amount of the per-operative opioids [9]. In our series we found a 38% reduction for remifentanil needed to ensure surgery, this saving allowed a better analgesia not only immediately postoperative, but even after the first day. From the first hour, both groups were comparable in morphine titration, but the amount required in the block group was lower than in the control group. The decreasing of morphine consumption reduces episodes of nausea and vomiting common for this type of surgery and the incidence varies from 21.7 to 63.3% depending on the series [2]. We report a statistically insignificant decrease of about 10% in episodes of nausea and vomiting. These effects could be the cause of post-operative complications such as bleeding and increased pain but there are no series that compared the impact of these adverse effects on the post-operative complication rate. Despite the low concentration of our product, we reported only one adverse event in the block group with difficulty breathing and difficulty in awakening, probably in relation to an extension of the block to the motor

nerves of the upper limbs and to the phrenic nerve. This complication is described primarily for the inter-scalenic block and for the superficial cervical plexus block [18-19]. We chose the volume of 10 ml of 0.25% bupivacaine. During the procedure, we noticed that the flooding of the interfascial space starts from 6 ml injected. The volume of 10 ml reported in our study and in the literature [20] remains arbitrary and encourages further studies with variable volumes to determine the optimum volume for the analgesic effect by minimizing side effects related to the local extension.

We report limits to our study where the delay between the block and the incision was not detected; tests of the sensitivity of the cervical region after block realization were not performed. Thus, the success rate found in our series can be overestimated. Patient satisfaction was assessed by a YES\NO binary scale.

Despite these shortcomings, we noticed the contribution of this technique to the per operative saving of remifentanil consumption and decreasing post-operative morphine requirement, as well as its immediate contribution to the postoperative analgesia, but also for better analgesia from post-operative H 12.

Conclusion

The realization of the bilateral intermediate cervical ultrasound-guided block in total thyroidectomy under general anesthesia allows a per and post-operative saving of the opioids consumption, gives better analgesia for the patients and allows a non-significant reduction of the episodes of nausea and vomiting. This technique allows a better patient's satisfaction but without a significant difference. Larger series are needed to determine the optimal volume and dose of local anesthetic and to document any statistically significant implications of the intermediate cervical block for adverse effects and patient satisfaction.

References

1. Millan SS, Wu LS, Sosa JA (2014) Thyroidectomy under local anaesthesia. *Curr Surgery Rep* 2: 37.
2. Warschkow R, Tarantino I, Jensen K, Beutner U, Clerici T, et al. (2012) Bilateral superficial cervical plexusblock in combination with general anesthesia has a low efficacy in thyroid surgery: a meta-analysis of randomized controlled trials. *Thyroid* 22: 44-52.
3. Ali S, Nilgün K, Raif U, Kadir S, Gül Ç, et al. (2016) Comparison of Combined (Deep and Superficial) and Intermediate Cervical Plexus Block by Use of Ultrasound Guidance for Carotid Endarterectomy. *Journal of Cardiothoracic and Vascular Anesthesia* 30: 317-322.
4. Arslane A, Pascal P, Benedicte D, Corinne J, Emmanuel S, et al. (2017) Ultrasound-guided intermediate cervical block versus superficial cervical block for carotid artery endarterectomy: The randomized-controlled CERVECHO trial. *Anaesth Crit Care Pain Med* 36: 91-95.
5. Miu M, Royer C, Gaillat C, Schaub B, Menegaux F, et al. (2016) Lack of Analgesic Effect Induced by Ropivacaine Wound Infiltration in Thyroid Surgery: A Randomized, Double-Blind, Placebo-Controlled Trial. *Anesth Analg* 122: 559-64.
6. Cockcroft DW, Gault MH (1976) Prediction of Creatinine Clearance from Serum Creatinine. *Nephron* 16: 31-41.
7. Aubrum F, Monsel S, Langeron O, Coriat P, Riou B (2001) Postoperative titration of intravenous morphine. *Eur J Anesthesiology* 18:159-165.
8. Kalmovich LM, Cote V, Sands N, Black M et al. (2010) Thyroidectomy:

- exactly how painful is it? *J Otolaryngol Head Neck surg* 39: 277-283.
9. Motamed C, Merle JC, Combes X, Vodinh J, Kouyoumoudjian C, et al. (2006) Postoperative pain scores and analgesic requirement after thyroid surgery: comparison of three intraoperative opioid regimens. *Int J Med Sci* 3: 11-3.
 10. Dieudonne N, Gomola A, Bonnichon P, Ozier YM (2001) Prevention of postoperative pain after thyroid surgery: a double-blind randomized study of bilateral superficial cervical plexus blocks. *Anesth Analg* 92:1538-1542.
 11. Eti Z, Irmak P, Gulluoglu BM, Manukyan MN, Gogus FY (2006) Does bilateral superficial cervical plexus block decrease analgesic requirement after thyroid surgery? *Anesth Analg* 102: 1174-1176.
 12. Herbland A, Cantini O, Reynier P, Valat P, Jougon J, et al. (2006) The bilateral superficial cervical plexus block with 0.75% ropivacaine administered before or after surgery does not prevent postoperative pain after total thyroidectomy. *Reg Anesth Pain Med* 31:34-39.
 13. Weintraud M, Marhofer P, Boisenberg A, Kapral S, Willschke H, (2008) Iliioinguinal/iliohypogastric blocks in children: where do we administer the local anesthetic without direct visualization? *Anesth Analg* 106: 89-93.
 14. Seidel R, Schulze M, Zukowski K, Wree A (2015) Ultrasound-guided intermediate cervical plexus block. *Anatomical study. Anaesthesist* 64: 446-450.
 15. Leblanc I, Chterev V, Rezik M, Boura B, Costanzo A, et al. (2015) Safety and efficiency of ultrasound-guided intermediate cervical plexus block for carotid surgery. *Anaesth Crit Care Pain Med*.
 16. Snyder SK, Roberson CR, Cummings CC, Rajab MH (2006) Local anesthesia with monitored anesthesia care vs general anesthesia in thyroidectomy: a randomized study. *Arch Surg* 141: 167-173.
 17. Gürkan Y, Taş Z, Toker K, Solak M (2015) Ultrasound guided bilateral cervical plexus block reduces postoperative opioid consumption following thyroid surgery. *J Clin Monit Comput* 29: 579-584.
 18. Riazi S, Carmichael N, Awad I, Holtby RM, McCartney CJ (2008) Effect of local anaesthetic volume (20 vs 5 ml) on the efficacy and respiratory consequences of ultrasound-guided interscalene brachial plexus block. *Br J Anaesth* 101: 549-556.
 19. Shih ML, Duh QY, Hsieh CB, Liu YC, Lu CH, et al. (2010) Bilateral superficial cervical plexus block combined with general anesthesia administered in thyroid operations. *World J Surg* 34: 2338-2343.
 20. Steffen T, Warschkow R, Brändle M, Tarantino I, Clerici T (2010) Randomized controlled trial of bilateral superficial cervical plexus block versus placebo in thyroid surgery. *Br J Surg* 97: 1000-1006.